

# Ovarian follicle count by magnetic resonance imaging is greater in adolescents and young adults with polycystic ovary syndrome than in controls

Camila Freitas Pereira-Eshraghi, M.D.,<sup>a</sup> Rachel Tao, B.A.,<sup>a</sup> Codruta C. Chiuzan, Ph.D.,<sup>b</sup> Yuan Zhang, M.S.,<sup>b</sup> Wei Shen, M.D.,<sup>c</sup> Jodi P. Lerner, M.D.,<sup>d</sup> Sharon E. Oberfield, M.D.,<sup>a</sup> and Aviva B. Sopher, M.D., M.S.<sup>a</sup>

<sup>a</sup> Division of Endocrinology, Diabetes and Metabolism, Department of Pediatrics, Columbia University Irving Medical Center, New York, New York; <sup>b</sup> Department of Biostatistics, Columbia University Irving Medical Center, New York, New York; <sup>c</sup> Department of Pediatrics and Nutrition, New York Obesity Center, Columbia University Irving Medical Center, New York, New York; and <sup>d</sup> Department of Obstetrics and Gynecology, Columbia University Medical Center, New York, New York

**Objective:** To use magnetic resonance imaging (MRI) to quantify the follicle number per ovary (FNPO) using biplanar measurements and determine the ovarian volume (OV) using three-dimensional measurements in adolescents and young adults with polycystic ovary syndrome (PCOS) and controls and compare the differences between these groups; to examine the relationships between FNPO and OV and metabolic markers associated with PCOS; to compare OV obtained by use of MRI and ultrasound between young patients with PCOS and controls.

**Design:** Cross-sectional study.

**Setting:** Outpatient within a major medical center in New York City.

**Patients:** Adolescent girls and young women aged 13–25 years with PCOS ( $n = 16$ ) and body mass index-, age-, and ethnicity-comparable control subjects ( $n = 15$ ).

**Interventions:** None.

**Main Outcome Measures:** The OV and FNPO by use of MRI, OV by use of transabdominal pelvic ultrasound, anthropometric measurements, and biochemical and hormonal evaluation.

**Results:** The FNPO was higher in participants with PCOS ( $23.7 \pm 4.6$  follicles) than in controls ( $15.2 \pm 4$  follicles) when adjusted for menstrual age. The OV by use of ultrasound was higher in participants with PCOS ( $11.7 \pm 5.6$  mL) than in controls ( $8.1 \pm 3.4$  mL); however, OV by use of MRI did not differ between the groups. The OV by use of MRI and ultrasound correlated in participants with PCOS ( $r = 0.62$ ) but not in controls.

**Conclusions:** Our results are in line with prior studies showing that FNPO may be a more sensitive measure of polycystic ovary morphology than OV. The results of this study support the use of ovarian  $k$ , a promising diagnostic tool for PCOS, in young patients. (Fertil Steril Rep® 2022;3:102–9. ©2022 by American Society for Reproductive Medicine.)

**Key Words:** Adolescents, ovarian follicle count, ovarian MRI, ovarian volume, PCOS

**Discuss:** You can discuss this article with its authors and other readers at <https://www.fertstertdialog.com/posts/xfre-d-21-00133>

Received September 14, 2021; revised January 27, 2022; accepted January 28, 2022.

C.F.P.-E. has nothing to disclose. R.T. has nothing to disclose. C.C.C. has nothing to disclose. Y.Z. has nothing to disclose. W.S. has nothing to disclose. J.P.L. has nothing to disclose. S.E.O. has nothing to disclose. A.B.S. has nothing to disclose.

Supported by National Institute of Diabetes and Digestive and Kidney Diseases (grant numbers: 5T32DK065522-14 and P30 DK26687) and the National Center for Advancing Translational Sciences, National Institutes of Health (grant number: KL2TR000081). The content is solely the authors' responsibility and does not necessarily represent the official views of the National Institutes of Health.

Reprint requests: Aviva B. Sopher, M.D., M.S., Division of Endocrinology, Diabetes and Metabolism, Department of Pediatrics, Columbia University Irving Medical Center, 622 West 168 Street, PH 17 West 308, New York, New York 10032 (E-mail: [ahs32@cumc.columbia.edu](mailto:ahs32@cumc.columbia.edu)).

Fertil Steril Rep® Vol. 3, No. 2, June 2022 2666-3341

© 2022 The Authors. Published by Elsevier Inc. on behalf of American Society for Reproductive Medicine. This is an open access article under the CC BY-NC-ND license (<http://creativecommons.org/licenses/by-nc-nd/4.0/>).

<https://doi.org/10.1016/j.xfre.2022.01.008>

The polycystic ovary syndrome (PCOS) affects 5%–15% of women of reproductive age and frequently manifests in adolescence (1–3). The diagnosis of PCOS in this young population can be challenging because its presentation frequently overlaps with the physiologic changes that occur during puberty (2).

The polycystic ovary syndrome is associated with multiple chronic comorbidities that significantly affect patients' lives and have major public health implications. These comorbidities affect both obese and nonobese patients with PCOS and include insulin resistance (65%–70%) (4, 5), type 2 diabetes (6), cardiovascular disease, dyslipidemia, hypertension (7), nonalcoholic fatty liver disease, infertility, endometrial cancer (8, 9), depression, anxiety, and eating disorders (10). Overall, PCOS is associated with a reduced health-related quality of life, with infertility and weight concerns having the most impact (11).

The diagnostic criteria for PCOS use different combinations of oligo/amenorrhea, clinical and/or biochemical hyperandrogenism, and polycystic ovary morphology (PCOM). The identification of PCOM has not been a useful diagnostic tool for PCOS in younger patients as its criteria were developed in adults using transvaginal ultrasound (12), a procedure that is considered invasive for adolescents and some young adults. The transabdominal pelvic ultrasound, although less invasive, is inferior in resolution, especially in obese patients. According to the Rotterdam criteria, PCOM is identified when the ovarian volume (OV) is >10 mL and follicle number per ovary (FNPO) is  $\geq 12$  small antral follicles of 2–9 mm in diameter (12). The Androgen Excess and Polycystic Ovary Syndrome Society (AEPCOS) Task Force increased the FNPO cutoff to 25 follicles for the identification of PCOM in adults when using newer ultrasound technology (e.g., transducer frequency of  $\geq 8$  MHz) to improve diagnostic specificity for PCOS (13). Most recently, international guidelines have recommended the cutoff of 20 FNPO when using an endovaginal ultrasound transducer with a frequency of 8 MHz and/or OV of  $\geq 10$  mL (14).

Ovarian morphology varies with age, which adds to the difficulty in using adult criteria in adolescents and young adults for the diagnosis of PCOS. The ovaries reach their maximum volume 1.2–3.8 years after menarche and slowly decrease in size through later adolescence and adulthood (15). The FNPO, specifically the number of small follicles, and OV increase during adolescence and young adulthood and decrease thereafter (16). Another limitation of using the presence of PCOM for the diagnosis of PCOS is that patients who have no other features of PCOS may have PCOM (17, 18). The prevalence of PCOM identified by FNPO in adults in the general population is 32% (17). A similar prevalence has been observed in adolescents. In two studies, PCOM was observed in 33% of adolescents in whom it had been at least two years after menarche and was not associated with an ovulatory dysfunction (18, 19). Current guidelines recommend the use of PCOM as a part of the diagnosis of PCOS only in women in whom it had been  $\geq 8$  years after menarche (14). These observations highlight the necessity of having an adolescent-specific definition of PCOM (2).

Magnetic resonance imaging (MRI) is a readily available modality that provides clear ovarian images (16); however, studies using MRI to evaluate ovarian morphology in PCOS, especially in adolescents and young adults, are scarce. Although a few available studies (20–23) show differences in mean FNPO and mean OV when individuals with PCOS and controls are compared, the paucity of available studies, the use of an approximate ellipsoid formula for the OV evaluation in most of the studies, the small sample sizes studied, and the nonuniform use of diagnostic criteria for PCOS all contribute to our lack of understanding of ovarian morphology in adolescents.

Magnetic resonance imaging is a promising modality that has the potential to better define adolescent ovarian morphology, to establish norms in adolescents, and as a diagnostic tool for PCOS; however, to date, its use is restricted to research. Whereas its main limitation is its cost, if it proves to improve the diagnostic accuracy for PCOS, the cost-benefit ratio may favor its use, especially for adolescents with atypical presentations of PCOS. Accurate and early diagnosis of PCOS in adolescents will most likely decrease anxiety associated with the diagnostic process, improve guidance and education, and hasten the initiation of treatment for truly affected young patients, potentially preventing or mitigating the long-term complications of PCOS (16).

This study aimed to contribute to the currently available knowledge regarding ovarian morphology in adolescents with PCOS by use of biplanar MRI as an imaging modality. Our primary aims were to quantify FNPO and measure OV by use of MRI. Our secondary aims were to examine the relationships between FNPO and OV with metabolic markers associated with PCOS and compare OV obtained by use of MRI and transabdominal ovarian ultrasound in individuals with PCOS and controls.

## MATERIALS AND METHODS

Adolescent girls and young women aged 13–25 years with PCOS ( $n = 16$ ) and age-, body mass index (BMI)-, and ethnicity-comparable controls ( $n = 15$ ) were recruited from general pediatric, adolescent, gynecology, and pediatric endocrinology clinics and faculty practices at Columbia University Irving Medical Center (CUIMC) in New York City from 2015 to 2019. The patients were those in whom it had been at least two years after menarche and were nonobese (BMI of <95th percentile for participants aged <20 years and <30 kg/m<sup>2</sup> for participants aged  $\geq 20$  years). The polycystic ovary syndrome was diagnosed using the National Institutes of Health criteria, which require the presence of hyperandrogenemia (hirsutism and/or acne vulgaris) and oligo/amenorrhea (4). Hirsutism was determined by a modified Ferriman-Gallwey hirsutism score of  $\geq 8$  (17), and hyperandrogenemia was determined according to the laboratory norms (Esoterix, Inc., Calabasas, CA). Using the phenotypic approach of AEPCOS, patients with PCOS in this study were characterized as phenotypes A (hyperandrogenism, ovarian dysfunction, and PCOM) and B (hyperandrogenism and ovarian dysfunction) (18). Control subjects were eumenorrheic without clinical or biochemical hyperandrogenism. The exclusion criteria for

TABLE 1

Demographic and clinical characteristics of 16 patients with PCOS versus 15 controls.

Characteristics	PCOS N = 16	Control N = 15	P value
Age (y)			
Mean (SD)	18.8 (3.4)	21.8 (2.5)	.03 <sup>a</sup>
Median (IQR)	17.8 (13–25.9)	20.5 (15.4–25.8)	
Menstrual age (y)			
Mean (SD)	6.7 (2.7)	9.3 (2.5)	< .01 <sup>a</sup>
Median (IQR)	5.8 (3.2–12)	9.1 (4.5–13.9)	
Race, n (%)	—	—	NS
African American	2 (12%)	2 (14%)	
Caucasian	7 (44%)	5 (33%)	
Hispanic	6 (38%)	5 (33%)	
Other	1 (6%)	3 (20%)	
BMI (kg/m <sup>2</sup> ), mean (SD)	23.3 (3.2)	22.8 (3)	.63
Weight, n (%)	—	—	—
Normal weight	13 (81%)	13 (87%)	—
Overweight	3 (19%)	2 (13%)	—
Body fat (%), mean (SD)	35.1 (6.8)	32.1 (6.3)	.22

Note: BMI = body mass index; IQR = interquartile range; NS = not significant; PCOS = polycystic ovary syndrome; SD = standard deviation.

<sup>a</sup>  $P < .05$ . P values were generated using Student's *t* test or  $\chi^2$  test/Fisher's exact test.

Pereira-Eshraghi. Ovarian morphology by MRI in adolescents with PCOS. *Fertil Steril Rep* 2022.

both groups included thyroid disease, diabetes mellitus, congenital adrenal hyperplasia, current or past pregnancy, and the use of metformin or hormonal contraception within three months before enrollment. The subjects were recruited by posted flyers, listserv announcements, and referrals from the pediatrics, adolescent, gynecology, and pediatric endocrinology services at CUIMC. A sample size of 16 subjects per group was calculated to achieve approximately 80% power to detect a minimum difference of 10 in FNPO, with an equal standard deviation as large as 10, on the basis of a 2-sided Student's *t* test with a significance level of .05. The same sample size was calculated to achieve 80% power to detect a minimum difference of five in the mean OV between the two groups, with a standard deviation of five.

This study was approved by the institutional review board at CUIMC. Informed consent was obtained from all participants aged  $\geq 18$  years. Parental consent and participant assent were obtained from all participants aged  $< 18$  years.

### Clinical Studies

Control subjects were evaluated during the early follicular phase of the menstrual cycle (day of cycle, one through seven); oligo/amenorrheic subjects were evaluated on any day. The clinical evaluation comprised medical history, physical examination, and anthropometric measurements, including the height measured using a calibrated stadiometer to the nearest 0.1 cm and weight measured using a digital readout scale to the nearest 0.1 kg. The body mass index was calculated.

### Laboratory Studies

Blood was drawn after an overnight fasting between 8 AM and 9 AM and included the following: thyroid function tests, prolactin; 17-hydroxyprogesterone, estradiol, androstenedi-

one (high-pressure liquid chromatography/tandem mass spectrometry by Esoterix, 11.8–18.6 years: 50–224 ng/dL, 18–40 years: 28–230 ng/dL) and dehydroepiandrosterone sulfate (DHEA-S) (high-pressure liquid chromatography/tandem mass spectrometry by Esoterix, 11.8–18.6 years: 44–248  $\mu\text{g/dL}$ , 21–30 years: 22–372  $\mu\text{g/dL}$ ); antimüllerian hormone (AMH) (electrochemiluminescence; 7–19 years: 0.53–7.78 ng/mL, 20–25 years: 1.05–12.86 ng/mL, by Esoterix), luteinizing hormone (LH) and follicle-stimulating hormone (chemiluminescence immunoassay by Esoterix, pubertal females aged  $< 20$  years: 36–125 nmol/L, 20–49 years: 24.6–122 nmol/L), testosterone (liquid chromatography/mass spectrometry by Esoterix, 11.8–18.6 years: 20–38 ng/dL,  $> 18$  years: 10–55 ng/dL); free testosterone (equilibrium dialysis by Esoterix, 0.8%–1.4% free, 1.1–6.3 pg/mL); and two-hour oral glucose tolerance test after a 75-g Glucola (Fisher Scientific, Hampton, NH) challenge with measurement of glucose and insulin at 0, 30, 60, 90, and 120 minutes. The level of insulin was measured using immunochemiluminescence assay, and the glucose level was analyzed using the glucose hexokinase method (Biomarkers Core Laboratory at CUIMC). The insulin area under the curve (iAUC) (24) and homeostatic model assessment for insulin resistance (HOMA-IR) were calculated (25).

### Biplanar MRI and Three-Dimensional Volumetric Study

The T2-weighted images of the pelvis were obtained to evaluate the presence of PCOM in axial, coronal, and sagittal planes on a 1.5T whole-body Signa 'LX' MRI system (General Electric, Milwaukee, WI). The in-plane pixel size was 0.7 mm  $\times$  0.7 mm, and the slice thickness was 6 mm. The follicle number per ovary was obtained in two planes (i.e., cross-sectional and

TABLE 2

Endocrine evaluation and ovarian morphology by ultra-sound and magnetic resonance imaging in 16 patients with PCOS versus 15 controls.

Characteristics	PCOS	Control	P value
	N = 16	N = 15	
Testosterone (ng/dL)	48.9 (17.2)	26.1 (7.6)	< .0001
Free testosterone (pg/mL)	6.1 (2.2)	2.4 (1.1)	< .0001
SHBG (ng/dL)	52.6 (63.8)	64.3 (27.8)	.02
LH (mIU/mL)	14.2 (10.8)	6.7 (3.7)	.007
FSH (mIU/mL)	5.6 (1.9)	6.7 (2.1)	.15
Estradiol (pg/mL)	96.2 (109.5)	40.9 (24)	.07
Androstenedione (ng/dL)	219.3 (75.8)	116 (41)	< .001
DHEA-S ( $\mu$ g/dL)	301.5 (89.9)	205.7 (70.3)	.003
AMH (ng/mL)	11.8 (5.5)	4.8 (2.3)	.0001
HOMA-IR	5.5 (6.9)	1.5 (0.9)	.08
iAUC	116.4 (53.4)	95.5 (52)	.18
OV by use of MRI (mL)	11.5 (3.3)	10.8 (3.7)	.59
OV by use of US (mL)	11.7 (5.6)	8.1 (3.4)	.04
FNPO	23.7 (4.6)	15.2 (4)	< .0001

Note: Values are reported as means  $\pm$  standard deviation. P values were generated using Student's t test or Wilcoxon's rank sum test. AMH = antimüllerian hormone; DHEA-S = dehydroepiandrosterone sulfate; FNPO = follicle number per ovary; FSH = follicle-stimulating hormone; HOMA-IR = homeostatic model assessment for insulin resistance; iAUC = insulin area under the curve; LH = luteinizing hormone; MRI = magnetic resonance imaging; OV = ovarian volume; PCOS = polycystic ovary syndrome; SHBG = sex hormone binding globulin; US = ultrasound.

Pereira-Eshraghi. Ovarian morphology by MRI in adolescents with PCOS. Fertil Steril Rep 2022.

coronal planes) (16) and grouped by size (2–6 mm, 6–9 mm, 9–12 mm, and >12 mm). The follicles that measured 2–9 mm were counted to determine FNPO. The ovarian volume was calculated by summarizing the manually traced ovarian area on each axial slice and slice thickness. The MRI analyses were performed by a trained and experienced analyst (W.S.) in the Image Analysis Core Laboratory of New York Obesity Nutrition Research Center using image analysis software sliceOmatic 5.0 (Tomovision Inc, Montreal, Canada). The MRI analyst was blinded to the clinical information.

A total body dual-energy roentgenogram absorptiometry (Hologic, Marlborough, MA) for lean and fat mass and

percentage body fat were obtained and interpreted by a certified clinical densitometrist (A.B.S.).

Transabdominal pelvic ultrasound was used to measure OV and performed using Voluson E8 machine (GE Healthcare, Chicago, IL) with a 1–5-MHz curved array transducer and analyzed by an expert in gynecologic ultrasonography (J.P.L.). Both the sonographer and analyzer were blinded to the diagnosis of the study subject. The ovarian volume was estimated by the simplified prolate ellipsoid formula: (length  $\times$  width  $\times$  height)/2 (26). The follicle number per ovary was not measured by use of ultrasound because the transabdominal route is not appropriate for a precise follicle count assessment (13).

TABLE 3

Correlation coefficients between androgens, LH, AMH and markers of insulin resistance and ovarian morphology by MRI and by US in all 31 study participants.

Endocrine parameters	Mean FNPO	Mean OV by use of MRI	Mean OV by use of US
Free testosterone <sup>a</sup>	0.55	0.05	0.39
	$P=$ .0013	$P=$ .8	$P=$ .03
Androstenedione <sup>a</sup>	0.51	0.33	0.27
	$P=$ .0036	$P=$ .07	$P=$ .14
DHEA-S <sup>a</sup>	0.32	0.07	0.28
	$P=$ .085	$P=$ .72	$P=$ .12
LH <sup>b</sup>	0.46	0.12	0.49
	$P=$ .0085	$P=$ .52	$P=$ .0051
AMH <sup>b</sup>	0.86	0.32	0.32
	$P<$ .0001	$P=$ .09	$P=$ .1
HOMA-IR <sup>b</sup>	0.123	0.07	–0.02
	$P=$ .511	$P=$ .72	$P=$ .93
iAUC <sup>b</sup>	0.25	0.21	0.07
	$P=$ .17	$P=$ .25	$P=$ .68

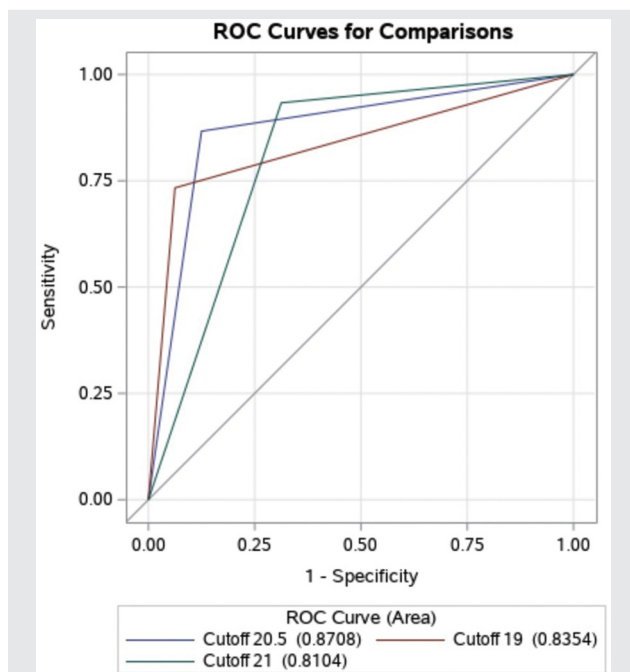
Note: AMH = antimüllerian hormone; DHEA-S = dehydroepiandrosterone sulfate; FNPO = follicle number per ovary; HOMA-IR = homeostatic model assessment for insulin resistance; iAUC = insulin area under the curve; LH = luteinizing hormone; MRI = magnetic resonance imaging; OV = ovarian volume; US = ultrasound.

<sup>a</sup> Values reported are Pearson's correlation coefficient and P values.

<sup>b</sup> Values reported are Spearman's correlation coefficient and P values.

Pereira-Eshraghi. Ovarian morphology by MRI in adolescents with PCOS. Fertil Steril Rep 2022.

FIGURE 1



Receiver operating characteristic curve for different cutoff values of mean follicle number per ovary. ROC = receiver operating characteristic.

Pereira-Eshraghi. Ovarian morphology by MRI in adolescents with PCOS. *Fertil Steril Rep* 2022.

## Data Analysis

Descriptive statistics were used to summarize all variables of interest. Continuous variables were described using means and standard deviations and/or medians and interquartile ranges. Comparisons between the two groups (PCOS vs. control) were assessed using two-sample independent Student's *t* tests or equivalent nonparametric tests for nonnormal data. The linear regression models were fitted to assess the associations between mean FNPO and PCOS vs. control groups, with adjustment for menstrual age. Categorical variables were summarized using frequencies (percentages). Additionally, Pearson's or Spearman's correlation coefficients were calculated to quantify the strength of association between morphological features (mean FNPO and mean OV by use of MRI and ultrasound) with hormonal levels and between the volumes as read by MRI and ultrasound. The discriminatory ability of different cutoff values for FNPO in classifying participants with PCOS vs. controls was evaluated using specificity, sensitivity, and the area under the receiver operating characteristic curve (area under the curve [AUC] and 95% confidence interval [CI]). Data analysis was performed using SAS v 9.4 (Cary, NC) with a level of significance of .05.

## RESULTS

Descriptive statistics are shown in Table 1. Patients with PCOS were younger than controls ( $P=.03$ ) and menstrual age, time

in years from menarche to age at the time of the study, was shorter in those with PCOS than in controls ( $P=.01$ ). Twelve participants (39%) were Caucasian, 11 (36%) were Hispanic, 4 (13%) were African American, and 4 (13%) were classified as "other." The "other" category comprised mostly multiracial participants.

Participants from both groups were nonobese and had similar BMIs and percentage body fat (Table 1). Laboratory evaluation showed that participants with PCOS had higher levels of androgens (testosterone, free testosterone, DHEA-S, and androstenedione), AMH, and LH and lower levels of sex hormone binding globulin than controls ( $P<.05$  for all). Estradiol and follicle-stimulating hormone levels did not differ between the groups (Table 2).

Analysis of ovarian morphology showed a higher FNPO in participants with PCOS ( $23.7 \pm 4.6$  follicles) than in controls ( $15.2 \pm 4$  follicles) ( $P<.0001$ ). Patients with PCOS had, on average, eight more follicles per ovary than controls when adjusting for menstrual age ( $P=.0001$ ). The participants with PCOS had higher OV ( $11.7 \pm 5.6$  mL) by use of transabdominal ultrasound than controls ( $8.1 \pm 3.4$  mL) ( $P=.04$ ). The ovarian volume by use of MRI did not differ between the groups (participants with PCOS:  $11.5 \pm 3.3$  mL; controls:  $10.8 \pm 3.7$  mL;  $P=.11$ ) (Table 2). The ovarian volume by use of MRI and ultrasound correlated in the PCOS group ( $r = 0.62$ ,  $P=.01$ ) but not in controls ( $r = 0.13$ ,  $P=.64$ ). The follicle number per ovary positively correlated with the levels of testosterone, androstenedione, LH, and AMH ( $P<.01$  for all) but did not correlate with HOMA-IR or iAUC. Neither OV by use of MRI nor ultrasound correlated with the levels of androgens, reproductive hormones, AMH, or markers of insulin resistance in either group (Table 3).

The receiver operating characteristic curves with different FNPO cutoff values were constructed and AUC was calculated for the diagnosis of PCOS (Fig. 1). The follicle number per ovary threshold of 20.5 for the mean FNPO showed the highest AUC of 0.87 (95% CI, 0.75–0.99) (Fig. 1).

The linear regression models were fitted to adjust for menstrual age, a potential confounder of the association between PCOS status and mean FNPO. The PCOS status, menstrual age, and AMH levels were considered potential predictors of FNPO. When analyzed separately in univariable models, all three variables were associated significantly with FNPO. Because of the high collinearity between the AMH levels and PCOS, the AMH levels were removed from the model. In the multivariable model, including both PCOS status and menstrual age, PCOS status remained a significant predictor of FNPO, whereas menstrual age did not. Regression results showed that having PCOS increased mean FNPO by approximately eight follicles ( $P<.0001$ ) after adjusting for menstrual age (Supplemental Table 1, available online).

## DISCUSSION

In the present study, FNPO by use of biplanar MRI was higher in participants with PCOS ( $23.7 \pm 4.6$  follicles) than in controls ( $15.2 \pm 4$  follicles) ( $P<.0001$ ) when adjusted for menstrual age. The values in both groups are higher than the value for FNPO of 12 suggested by the Rotterdam criteria

(12) and the most recent international guidelines of 2020 (14) but lower than that suggested by AEPCOS criteria of 25 (13). We found that a cutoff value of 20.5 follicles differentiates between the participants with PCOS and controls in our young population and that the participants with PCOS had a mean FNPO of eight follicles greater than controls. The follicle number per ovary had moderate-to-strong positive correlations with free testosterone, androstenedione, DHEA-S, LH, and AMH levels but did not correlate with HOMA-IR or iAUC, suggesting that FNPO by use of biplanar MRI is a strong marker for the hormonal changes typical of PCOS but not for the insulin resistance. Overall, FNPO by use of biplanar MRI appears to be an excellent marker for PCOS in young patients.

The ovarian volume by use of MRI was obtained using real three-dimensional volume, and it did not appear to be as strong a marker for PCOS as FNPO in our population. The ovarian volume by use of ultrasound was higher in participants with PCOS ( $11.7 \pm 5.6$  mL) than in controls ( $8.1 \pm 3.4$  mL) ( $P=.04$ ); however, OV by use of MRI did not differ between the groups. Additionally, OV by use of MRI did not correlate with the hormonal levels and metabolic markers studied.

Our results confirmed the findings of prior studies that have examined the use of FNPO in adolescents (20, 23) and adults (20, 25). The PCOS ovaries have a greater number of growing follicles than non-PCOS ovaries without a consistent effect on primordial follicle number. The preantral follicles accumulation is believed to be a result of slowed follicle development through the primary stage along with a prolonged survival pattern (27). The age-related decline in antral follicles has been shown by use of transvaginal ultrasound (15) and ovarian MRI (16). Notably, the mean FNPO of  $23.7 \pm 4.6$  observed in this study in participants with PCOS and  $15.2 \pm 4$  in controls was similar to those reported in the previous studies in adolescents by use of MRI (20, 23). In addition, interestingly, the cutoff value of 20.5 for the mean FNPO showed the highest AUC of 0.87 (95% CI, 0.75–0.99) and is similar to the cutoff of 20 recommended by the recent guidelines when detecting FNPO in women in whom it had been  $\geq 8$  years after menarche and by use of transvaginal ultrasound with newer technologies. In this study, OV by use of MRI correlated with OV by use of ultrasound, as has been reported (20). The mean OV by use of ultrasound was higher in patients than in controls but was not different between the groups with MRI. It is important to highlight that OV by use of MRI captured the real three-dimensional volume of the ovaries. This is in contrast to most studies that have analyzed ovarian morphology by use of MRI, which used the ellipsoid formula to estimate OV (20, 23, 28), the same method used when calculating OV by use of ultrasound. The OV by use of ultrasound is known to have less diagnostic potential for PCOM than FNPO in adults (13). Based on our experience, a possible explanation for the lack of difference in OV between participants with PCOS and controls using MRI is that PCOS ovarian follicles are smaller and more numerous than ovarian follicles in controls. Although numerous, small follicles potentially would not significantly affect OV. Patients with PCOS tend to have more ovarian hilum and stroma than controls; however, this may not contribute significantly to an OV difference in younger patients.

In the present study, participants with PCOS presented typical hormonal profiles for the syndrome. The levels of AMH were also higher in participants with PCOS than controls, as expected, and correlated with FNPO by use of biplanar MRI. Several studies have suggested that the AMH level is a useful marker for PCOM (28–32); however, its use is limited because of issues with assay accuracy and reproducibility and the lack of an established threshold (13). We also found that the mean FNPO positively correlated with the androgen levels. Similar findings have been reported, for example, free testosterone levels were found to have a strong positive correlation with FNPO by use of MRI in adults with PCOS and controls (33).

Strengths of this study are that it is prospective, use of the National Institutes of Health criteria for the diagnosis of PCOS, use of the biplanar method for FNPO by use of MRI, and the three-dimensional approach for the calculation of OV by use of MRI, which is a more realistic method of measurement to quantify OV than the ellipsoid method. Limitations of this study are the small number of participants, which potentially limits the ability to detect differences between participants with PCOS and controls and the generalizability of the results; the small age difference between participants with PCOS and controls, which was accounted for in the statistical analysis; the absence of obese subjects who potentially have a different metabolic profile compared with the nonobese subjects. However, it is plausible to speculate that ovarian MRI would have shown to be useful in this specific population because the transabdominal ultrasound is more technically difficult in assessing ovarian morphology in obese patients, and MRI images are enhanced by the presence of adipose tissue.

Polycystic ovary syndrome is often unrecognized and underdiagnosed, especially in younger patients, despite its relatively high prevalence in the general population (3). One large population-based study in the United States reported that approximately 50% of adolescents with symptoms indicative of PCOS remained undiagnosed (3). Diagnostic evaluation of PCOS has been estimated to account for only 2% of the total mean annual cost of PCOS in women of reproductive age in the United States, which is  $>4$  billion dollars per year (11). This small percentage suggests that widespread screening for PCOS is potentially a cost-effective strategy that could lead to earlier diagnosis, intervention, and possibly amelioration and prevention of serious sequelae (34). Better diagnostic tools are needed for the diagnosis of PCOS in this young population because the PCOS phenotype is believed to be established in early adolescence regardless of BMI (35). The current criteria for diagnosis overlap with normal physiological features of puberty and the fact that there are no available PCOM criteria in this age group and the ultrasound should not be used as part of the diagnosis of PCOS in adolescents and young women in whom it has been  $<8$  years after menarche (14). Ovarian images using MRI have shown excellent reproducibility, interobserver agreement, and clarity (16). Moreover, MRI is noninvasive and can produce three-dimensional images, allowing for true volumetric determination of OV. The analysis of the cost of the two imaging modalities (MRI and

ultrasound) is out of the scope of this study. However, it is important to note that although ovarian MRI is more costly than ovarian ultrasound, ovarian MRI is potentially cost-effective if it leads to an earlier diagnosis in atypical cases, as it has been found to be in other pathologies (36, 37). Currently, there is no standard protocol for FNPO assessment using ovarian MRI; however, if this modality is found to be cost-effective, radiologists could learn how to interpret such images.

## CONCLUSION

In summary, these results support the use of biplanar ovarian MRI as a promising diagnostic tool for PCOS in young patients with the goal of providing these young patients with a more definitive diagnosis, treatment, and prevention of chronic disease. Further studies with a larger sample size and participants with different BMIs, including obese patients who were not included in this study, are needed to better characterize PCOM criteria relevant to adolescents and young adults and ultimately define thresholds of FNPO and OV to be used in the diagnosis of PCOS in this population. If ovarian MRI is proven to be useful in a larger sample of participants, cost-effective studies would be important to assess whether this imaging modality is feasible for the clinical investigation of patients with PCOS.

## REFERENCES

1. Norman RJ, Dewailly D, Legro RS, Hickey TE. Polycystic ovary syndrome. *Lancet* 2007;370:685–97.
2. Witchel SF, Oberfield SE, Peña AS. Polycystic ovary syndrome: pathophysiology, presentation, and treatment with emphasis on adolescent girls. *J Endocr Soc* 2019;3:1545–73.
3. March WA, Moore VM, Willson KJ, Phillips DI, Norman RJ, Davies MJ. The prevalence of polycystic ovary syndrome in a community sample assessed under contrasting diagnostic criteria. *Hum Reprod* 2010;25:544–51.
4. DeUgarte CM, Bartolucci AA, Azziz R. Prevalence of insulin resistance in the polycystic ovary syndrome using the homeostasis model assessment. *Fertil Steril* 2005;83:1454–60.
5. Ovalle F, Azziz R. Insulin resistance, polycystic ovary syndrome, and type 2 diabetes mellitus. *Fertil Steril* 2002;77:1095–105.
6. Legro RS, Kunselman AR, Dodson WC, Dunaif A. Prevalence and predictors of risk for type 2 diabetes mellitus and impaired glucose tolerance in polycystic ovary syndrome: a prospective, controlled study in 254 affected women. *J Clin Endocrinol Metab* 1999;84:165–9.
7. Heida KY, Bots ML, de Groot CJ, van Dunné FM, Hammoud NM, Hoek A, et al. Cardiovascular risk management after reproductive and pregnancy-related disorders: a Dutch multidisciplinary evidence-based guideline. *Eur J Prev Cardiol* 2016;23:1863–79.
8. Haoula Z, Salman M, Atiomo W. Evaluating the association between endometrial cancer and polycystic ovary syndrome. *Hum Reprod* 2012;27:1327–31.
9. Barry JA, Azizia MM, Hardiman PJ. Risk of endometrial, ovarian and breast cancer in women with polycystic ovary syndrome: a systematic review and meta-analysis. *Hum Reprod Update* 2014;20:748–58.
10. Dokras A, Stener-Victorin E, Yildiz BO, Li R, Ottey S, Shah D, et al. Androgen Excess-Polycystic Ovary Syndrome Society: position statement on depression, anxiety, quality of life, and eating disorders in polycystic ovary syndrome. *Fertil Steril* 2018;109:888–99.
11. Gibson-Helm M, Teede H, Dunaif A, Dokras A. Delayed diagnosis and a lack of information associated with dissatisfaction in women with polycystic ovary syndrome. *J Clin Endocrinol Metab* 2017;102:604–12.
12. Rotterdam ESHRE/ASRM-Sponsored PCOS consensus workshop group. Revised 2003 consensus on diagnostic criteria and long-term health risks related to polycystic ovary syndrome (PCOS). *Hum Reprod* 2004;19:41–7.
13. Dewailly D, Lujan ME, Carmina E, Cedars MI, Laven J, Norman RJ, et al. Definition and significance of polycystic ovarian morphology: a task force report from the Androgen Excess and Polycystic Ovary Syndrome Society. *Hum Reprod Update* 2014;20:334–52.
14. Teede HJ, Misso ML, Costello MF, Docras A, Laaven J, Moran L, et al. Recommendations from the international evidence-based guideline for the assessment and management of polycystic ovary syndrome. *Fertil Steril* 2018;110:364–79.
15. Welt CK, Carmina E. Clinical review: lifecycle of polycystic ovary syndrome (PCOS): from in utero to menopause. *J Clin Endocrinol Metab* 2013;98:4629–38.
16. Aiyappan SK, Karpagam B, Vadanika V, Chidambaram PK, Vinayagam S, Saravanan KC. Age-related normogram for ovarian antral follicle count in women with polycystic ovary syndrome and comparison with age matched controls using magnetic resonance imaging. *J Clin Diagn Res* 2016;10:TC11–3.
17. Johnstone EB, Rosen MP, Neril R, Trevithick D, Sternfeld B, Murphy R, et al. The polycystic ovary post-Rotterdam: a common, age-dependent finding in ovulatory women without metabolic significance. *J Clin Endocrinol Metab* 2010;95:4965–72.
18. Mortensen M, Ehrmann DA, Littlejohn E, Rosenfield RL. Asymptomatic volunteers with a polycystic ovary are a functionally distinct but heterogeneous population. *J Clin Endocrinol Metab* 2009;94:1579–86.
19. Codner E, Villaruel C, Eyzaguirre FC, López P, Merino PM, Pérez-Bravo F, et al. Polycystic ovarian morphology in postmenarchal adolescents. *Fertil Steril* 2011;95:702–6.e1–2.
20. Yoo RY, Sirlin CB, Gottschalk M, Chang RJ. Ovarian imaging by magnetic resonance in obese adolescent girls with polycystic ovary syndrome: a pilot study. *Fertil Steril* 2005;84:985–95.
21. Barber TM, Alvey C, Greenslade T, Gooding M, Barber D, Smith R, et al. Patterns of ovarian morphology in polycystic ovary syndrome: a study utilising magnetic resonance imaging. *Eur Radiol* 2010;20:1207–13.
22. Kenigsberg LE, Agarwal C, Sin S, Shifteh K, Isasi CR, Crespi R, et al. Clinical utility of magnetic resonance imaging and ultrasonography for diagnosis of polycystic ovary syndrome in adolescent girls. *Fertil Steril* 2015;104:1302–9.
23. Brown M, Park AS, Shayya RF, Wolfson T, Su HI, Chang RJ. Ovarian imaging by magnetic resonance in adolescent girls with polycystic ovary syndrome and age-matched controls. *J Magn Reson Imaging* 2013;38:689–93.
24. Yeckel CW, Weiss R, Dziura J, Taksali SE, Dufour S, Burgert TS, et al. Validation of insulin sensitivity indices from oral glucose tolerance test parameters in obese children and adolescents. *J Clin Endocrinol Metab* 2004;89:1096–101.
25. Matthews DR, Hosker JP, Rudenski AS, Naylor BA, Treacher DF, Turner RC. Homeostasis model assessment: insulin resistance and beta-cell function from fasting plasma glucose and insulin concentrations in man. *Diabetologia* 1985;28:412–9.
26. Sample WF, Lippe BM, Gyepes MT. Gray-scale ultrasonography of the normal female pelvis. *Radiology* 1977;125:477–83.
27. Chang RJ, Cook-Andersen H. Disordered follicle development. *Mol Cell Endocrinol* 2013;373:51–60.
28. Fondin M, Rachas A, Huynh V, Franchi-Abella S, Teglas JP, Duranteau L, et al. Polycystic ovary syndrome in adolescents: which MR imaging-based diagnostic criteria? *Radiology* 2017;285:961–70.
29. Sopher AB, Grigoriev G, Laura D, Cameo T, Lerner JP, Chang RJ, et al. Anti-müllerian hormone may be a useful adjunct in the diagnosis of polycystic ovary syndrome in nonobese adolescents. *J Pediatr Endocrinol Metab* 2014;27:1175–9.
30. Hart R, Doherty DA, Norman RJ, Franks S, Dickinson JE, Hickey M, et al. Serum antimüllerian hormone (AMH) levels are elevated in adolescent girls with polycystic ovaries and the polycystic ovarian syndrome (PCOS). *Fertil Steril* 2010;94:1118–21.
31. Park AS, Lawson MA, Chuan SS, Oberfield SE, Hoeger KM, Witchel SF, et al. Serum anti-müllerian hormone concentrations are elevated in oligomenorrheic girls without evidence of hyperandrogenism. *J Clin Endocrinol Metab* 2010;95:1786–92.

32. Laven JS, Mulders AG, Visser JA, Themmen AP, De Jong FH, Fauser BC. Anti-müllerian hormone serum concentrations in normoovulatory and anovulatory women of reproductive age. *J Clin Endocrinol Metab* 2004;89:318–23.
33. Leonhardt H, Hellström M, Gull B, Lind AK, Nilsson L, Janson PO, et al. Ovarian morphology assessed by magnetic resonance imaging in women with and without polycystic ovary syndrome and associations with anti-müllerian hormone, free testosterone, and glucose disposal rate. *Fertil Steril* 2014;101:1747–56.
34. Azziz R, Marin C, Hoq L, Badamgarav E, Song P. Health care-related economic burden of the polycystic ovary syndrome during the reproductive life span. *J Clin Endocrinol Metab* 2005;90:4650–8.
35. Zore T, Lizneva D, Brakta S, Walker W, Suturina L, Azziz R. Minimal difference in phenotype between adolescents and young adults with polycystic ovary syndrome. *Fertil Steril* 2019;111:389–96.
36. Hagedorn KN, Hayatghaibi SE, Levine MH, Orth RC. Cost comparison of ultrasound versus MRI to diagnose adolescent female patients presenting with acute abdominal/pelvic pain using time-driven activity-based costing. *Acad Radiol* 2019;26:1618–24.
37. Gyftopoulos S, Guja KE, Subhas N, Virk MS, Gold HT. Cost-effectiveness of magnetic resonance imaging versus ultrasound for the detection of symptomatic full-thickness supraspinatus tendon tears. *J Shoulder Elbow Surg* 2017;26:2067–77.